



PATIENT

JJ Sims

PRESENTING CLINICAL SIGNS

History: Previous stray, recently adopted. Moderate to severe murmur. Assess prior to neuter.

SPECIES

Canine

ECHOCARDIOGRAM FINDINGS

2D, m-mode, color flow and doppler imaging is available. Normal mitral valve leaflets with no obvious prolapse into the left atrial lumen. No mitral regurgitation. Normal left atrial dimension. Normal LV diameter with normal myocardial function. The LV wall thickness is normal. The tricuspid valve appears normal in form and function. No right atrial dilation. Mild right ventricular prominence with mild hypertrophy. Mild to moderate elevation of pulmonic outflow velocities is suspected (doppler likely an underestimation). The PV appears thickened; however, the region is not extensively visualized. Mild post-stenotic dilatation of the branch PA's. Mild pulmonic insufficiency. The aortic valve appears to have normal morphology and mobility. Normal LVOT velocity. No pericardial or pleural effusion noted. No obvious cardiac masses.

BREED

Great Dane Mix

SEX

Male

CARDIAC CHART

AGE

5 months

WEIGHT

33lbs

INTERPRETED BY

Maggie Machen Lamy,
DVM, DACVIM
(Cardiology)

CANINE CARDIAC PARAMETERS	MR VMAX (m/s)	TR VMAX (m/s)	LA/AO (Boon method)	LA/AO (Heart Base; Swe)	FS (%)	EF (%)	EPSS (cm)
NORMAL PARAMETER	4.5-5.5	<2.7	1.3	<1.6	28-40	40-100	<0.6
PATIENT	NA	NA	NM	1.3	40	72	0.27
CANINE CARDIAC PARAMETERS	HR (BPM)	AV VMAX (m/s)	PV MAX (m/s)	BODY WEIGHT (kg)	LA 2D short axis Base view (cm)	LVIDd Avg; 2D and m-mode short axis (cm)	LVIDs Avg; 2D and m-mode short axis (cm)
NORMAL PARAMETER	50-100	0.7-1.7	0.7-1.6	BELOW	BELOW	BELOW	BELOW
PATIENT	200	1.3	3.44	15.0	2.4	2.9	1.8
*Normal chamber parameters expressed as a mean value (SD)				3	1.27 (5.3)	2.46 (2.46)	1.36 (5.5)
BODY WEIGHT DEPENDENT PARAMETERS				5	1.40 (4.5)	2.74 (5.2)	1.60 (4.7)
<i>*Note: All measurements based upon multi-modal images and methods. An average value is reported.</i>				10	1.50 (3.8)	3.27 (3.5)	2.06 (3.1)
				15	1.83 (2.0)	3.71 (2.4)	2.43 (2.1)
				20	2.02 (1.9)	4.14 (2.2)	2.80 (2.0)
				25	2.18 (2.4)	4.48 (2.9)	3.10 (2.5)
				30	2.33 (3.3)	4.83 (3.9)	3.39 (3.4)
				35	2.48 (4.3)	5.17 (5.0)	3.69 (4.5)
				40	2.62 (5.2)	5.48 (6.1)	3.96 (5.4)
				50	2.88 (7.1)	6.07 (8.3)	4.46 (7.4)

INTERPRETATION OF THE FINDINGS & FURTHER RECOMMENDATIONS

Elevated flow velocity through the pulmonary artery is noted, consistent with congenital pulmonic stenosis. No sub or supravalvular components were identified at this time; however, these are not entirely ruled out in this image set. A purely valvular stenosis is most likely given the thickening of the valve. The degree of obstruction is suspected to borderline mild/moderate based upon the appearance of the right heart. No tricuspid regurgitation or other issues are noted.

DATE

9/26/21

INVOICE

21217

REFERRING VET

Dr. Moore

HOSPITAL NAME

Thorton Animal Hospital

Lindsey Daniel,
DVM

IMAGING PERFORMED BY



PATIENT

JJ Sims

SPECIES

Canine

BREED

Great Dane Mix

SEX

Male

AGE

5 months

WEIGHT

33lbs

INTERPRETED BY

Maggie Machen Lamy,
DVM, DACVIM
(Cardiology)

IMAGING PERFORMED BY

Lindsey Daniel,
DVM

HOSPITAL NAME

Thorton Animal
Hospital

REFERRING VET

Dr. Moore

INVOICE

21217

DATE

9/26/21

Mild PS cases typically do not impact a patient clinically, and most are able to live a normal life free of complications. Moderate PS cases fall within a grey zone however, as most patients will not experience clinical signs (syncope, right-sided congestive heart failure) throughout their lifetime, however risk for progression to clinical signs will always remain. **A major concern in a young dog is that there is certainly room for progression up to 1 year of age.**

Medical management with atenolol is often recommended in moderate or severe cases, with mild often not requiring therapy. I would not institute Atenolol at this time based upon what is seen here. **That being said, highly recommend referral in this case for more extensive evaluation to determine if medications/surgery are indicated. If declined, reassessment is recommended in 6 months to determine if treatment is indicated.**

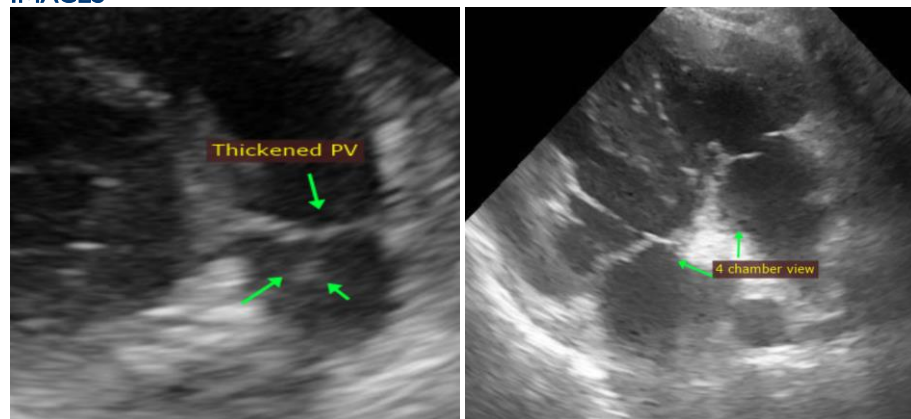
Anesthetic risk is considered mildly elevated. Avoid heart rate stimulating drugs such as atropine or glycopyrrolate. Avoid excessive vasodilation/hypotension. Pre-oxygenate for 5-10 minutes prior to induction. A reasonable protocol would be as follows: premedicate with opioid/benzodiazepine, propofol or alfaxalone induction, isoflurane maintenance. Monitor ECG, BP as is standard. Monitor for hypoxia in recovery; utilize O2 chamber if needed. Mild IV fluid restriction is advised.

Monitor for development of associated clinical signs (exertional collapse, abdominal distention, cough, labored breathing). Omega fatty acid supplementation may have some long-term benefit, given that these cases are predisposed to development of arrhythmias going forward. Breeding is not advised as this condition is genetically linked.

PLAN

No obvious indication for medications at this time. Recommend referral as discussed. If declined, recommend recheck echocardiogram in 6 months screen for progression.

IMAGES





PATIENT

JJ Sims

The information and recommendations provided are based on the images presented by the referring veterinarian. No evaluation can be communicated regarding pathology that was not visible in the image/video clips provided.

SPECIES

Canine

Thank you for this referral. This report was generated using transcription software, and minor dictation errors may be present. If the clinical or image interpretation does not parallel your findings or if I can be of any further assistance, please contact me.

BREED

Great Dane Mix

Maggie Machen Lamy, DVM
Diplomate of the American College of Veterinary Internal Medicine (Cardiology)
info@sonopath.com

SEX

Male

AGE

5 months

WEIGHT

33lbs

INTERPRETED BY

Maggie Machen Lamy,
DVM, DACVIM
(Cardiology)

**IMAGING
PERFORMED BY**

Lindsey Daniel,
DVM

HOSPITAL NAME

Thorton Animal
Hospital

REFERRING VET

Dr. Moore

INVOICE

21217

DATE

9/26/21